

# Efficacy and safety in the use of stent-retrievers for treatment of cerebral vasospasms after subarachnoid hemorrhage

Interventional Neuroradiology

1–8

© The Author(s) 2022

Article reuse guidelines:

sagepub.com/journals-permissions

DOI: 10.1177/15910199221086389

journals.sagepub.com/home/ine



J Hensler<sup>1</sup> , F Wodarg<sup>1</sup> , J Madjidyar<sup>2</sup>, S Peters<sup>1</sup>, G Cohrs<sup>3</sup>,  
O Jansen<sup>1</sup> and N Larsen<sup>1</sup>

## Keywords

Cerebral ischemia, subarachnoid hemorrhage, delayed cerebral ischemia, cerebral vasospasm

Received 21 October 2021; accepted: 21 February 2022

## Introduction

Cerebral vasospasms are one of the most important causes of morbidity and mortality after subarachnoid hemorrhage (SAH). Spasms usually occur between day 3–14 after bleeding, with a peak around the 7th day and with an incidence of about 30%.<sup>1</sup> While the term “vasospasm” describes the morphological state of pathological vasoconstriction in angiography, clinically significant vasospasm and cerebral ischemia are referred to as “delayed cerebral ischemia” (DCI). The pathophysiology of this disease is complex and multifactorial, with the contact of blood breakdown products with the abluminal vessel playing a crucial role.<sup>2</sup> The diagnosis can be confirmed by transcranial Doppler sonography (TCD), cross-sectional imaging with angiography, perfusion imaging and by digital subtraction angiography (DSA), which remains the gold standard.<sup>3</sup>

Treatment of vasospasm includes conservative and interventional approaches. However, a recent study provided Class III evidence that a frequent and early endovascular therapy to treat vasospasm reduces the risk of DCI and improves functional outcome.<sup>4</sup> In interventional therapy, intra-arterial nimodipine administration is simple and safe, but not always effective and durable to clinical experience. Additionally, there is a lack of data in the literature regarding this therapy.<sup>5</sup>

Percutaneous balloon-PTA for severe proximal vasospasms is angiographically effective and longer-lasting in most cases but carries considerable risks such as vascular rupture and interrupted blood flow during the PTA.<sup>6</sup> Therapy practices vary considerably, and optimal management remains controversial.<sup>7</sup> Self-expanding stent-retrievers are increasingly being used in interventional stroke therapy and seem to be a promising alternative to balloon-PTA in interventional spasmolysis due to their low periprocedural complication rates. However, only a few reports are available so far and it is not yet known how effective and safe this novel approach is, especially regarding the radial force of the retriever and the duration

of the effect.<sup>8–10</sup> We hereby report our single center experiences with interventional treatment of vasospasms using passive and active expandable stent-retrievers.

## Materials and methods

### Study design

We retrospectively included all patients between 2017 and 2020 that underwent stent retriever angioplasty with the use of stent-retrievers or Comaneci remodeling device (Rapid medical, Yokneam, Israel) in our department. Patients were referred to DSA when vasospasm was presumed due to clinical deterioration and/or suspected on TCD, CTP, CTA or MRA with an interdisciplinary consensus between neurosurgeons and neuroradiologists.

### Endovascular procedure

All interventional procedures were performed with a bi-plane Philips Allura-Xper-20/10 angiographic x-ray system via a transfemoral access. For stent retriever angioplasty the TrevoXP<sup>®</sup> 3 mm or 4 mm (Stryker, MI, USA), the pREset lite<sup>®</sup> 3 mm (Phenox, Germany) and Tigertriever (Rapid medical, Yokneam, Israel) stent-retrievers were used in a bi- or tri-axial approach. Moreover, the adjustable neck-bridging-devices Comaneci and Comaneci petit were used likewise. Radial force was adapted to visual

<sup>1</sup>Department of Radiology and Neuroradiology, Universitätsklinikum Schleswig-Holstein, Kiel, Germany

<sup>2</sup>Interventional Neuroradiology, UniversitätsSpital Zürich, Zürich, Switzerland

<sup>3</sup>Pediatric Neurosurgery, Charite University Hospital Berlin, Berlin, Germany

### Corresponding author:

Johannes Hensler, MD, Department of Radiology und Neuroradiology, Universitätsklinikum Schleswig-Holstein, Campus Kiel, Arnold-Heller-Str. 3, 24105 Kiel, Germany.

Email: [Johannes.hensler@uksh.de](mailto:Johannes.hensler@uksh.de)

restoration of vessel lumen with the adjustable devices. The stent-retrievers were deployed more passively in the more distal segments and in a “puff and fluff” technique in the more proximal segments. The devices were deployed for 30 s to 5 min in the affected vessel segments and resheathed while maintaining the position. Heparin was not routinely administered separately, still, a heparinized saline flushing solution is standard equipment for intra-arterial catheter interventions in our department. Additional balloon-PTA was performed if necessary. Nimodipine was administered intra-arterially before or after stent retriever angioplasty to treat the more peripheral vasospasms up to 5 mg per treated vessel.

### *Clinical and radiological assessments*

Assessment of the treatment result was carried out by two independent readers who evaluated the initial, intra-procedural and final DSA images for the presence and grading of vasospasms. Stenosis in vasospasms was graded by decrease in luminal diameter compared to the closest unaffected vessel segment according to NASCET criteria and difference of stenosis before and after retriever deployment was documented as reduction of stenosis. The result was rated as good with a persisting stenosis of  $\leq 30\%$ , medium with a remaining stenosis of 31–50% and poor with a narrowing of  $> 50\%$  after stent-retriever therapy. To evaluate the bio-mechanical properties of the stent-retrievers for the treatment of vasospasms each deployment in different vessel segments was assessed separately. Clinical outcome was evaluated according to the modified Rankin Scale. Statistical analysis was performed with Jamovi (The jamovi project (2020). jamovi (Version 1.2)). A Shapiro–Wilk test was employed to determine if a continuous variable was normally distributed. Mann–Whitney U test was used for comparison of the restoration of vessel-diameter in distal and proximal vessel-segments. A P-value  $< 0.05$  was considered significant.

### *Ethical approval*

All procedures performed in studies involving human participants were in accordance with the ethical standards of the institutional and/or national research committee and with the 1964 Helsinki declaration and its later amendments or comparable ethical standards. For this type of study formal consent is not required.

## **Results**

### *Patient and vasospasm characteristics*

This retrospective study was conducted according to the regulations of the institutional ethics committee. N=12 patients with cerebral vasospasm after SAH with n=21 affected vessel-segments were treated with stent-retrievers or Comaneci device for angioplasty. Table 1 shows a summary of the treated patients. The median age of the treated patients was 51 (range 32–78) years, 5 (41.7%)

of 12 patients were male. The two non-aneurysmal patients had an angiogram-negative perimesencephalic SAH. The vasospasms were found both in the anterior and posterior circulation, specifically in the M1-segment (7/21 segments, 33.3%) and overlapping M1/2- and A1/2-segments (7/21 segments, 33.3%) down to the M2- and A2/3-segments (5/21 segments, 23.8%), which are rated as “distal” segments in the statistics. In one patient the procedure was conducted in the basilar artery. In 4 of 12 patients (33.3%) the vasospasms were symptomatic, in 7 intubated patients (58.3%) and in one asymptomatic patient the diagnosis was confirmed by either CT-P, MRI or TCD. Overall CT-P was diagnostic in 9, MRI in 2 and TCD in 1 of 12 patients, respectively. However, pre-procedure clinical status was poor in 11 of 12 patients including the intubated and sedated patients with an mRS of 5.

### *Treatment*

In most of the segments the Trevo 4 mm (8/21 segments, 38.1%) and the Trevo 3 mm (7/21 segments, 33.3%) were used. In two segments the pREset lite 3 mm and the Comaneci petit were used, respectively. The Tigertriever 21 and Comaneci were each used once. Table 2 summarizes the treated segments and the type of stent-retrievers used. The type and size of retriever was up to the examiner and was visually adjusted to the affected segments. Only one type of retriever was used in each segment. Figure 1 shows an example of successful stent-retriever-spasmolysis over a long vessel segment (A2-A3) with very good restoration of the vessel lumen (segment 16). In Figure 2 the use of the adjustable Comaneci petit is shown with good effect in M1-segment. In all cases, a considerable increase of the stent-retriever diameter was already observed within the first 10 s after deployment. The increase of the lumen diameter was confirmed by direct visual assessment of the radiopaque stent struts on non-subtracted images and with repeated angiographies.

### *Radiologic results*

A good result with a remaining stenosis of  $\leq 30\%$  was achieved in 10/21 segments (47.6%), a medium result in 9/21 segments (42.9%) segments. In only two segments (9.5%), the persisting stenosis after retriever angioplasty was  $> 50\%$ . In two segments with moderate result an additional balloon-PTA was performed in the same vessel-segment to achieve a good restoration of the lumen. In 3/21 segments a balloon-PTA of more proximal vessel segments (C7 segment of the ICA) was conducted to improve overall brain perfusion. Local intra-arterial nimodipine (up to 5 mg per vessel) was administered in most segments (16/21; 76.2%): in 6/21 segments (28.6%) before and in 9/21 segments (42.9%) after the retriever-PTA, whereas in 1/21 segments (4.8%) nimodipine was administered during retriever-PTA. In addition, the continuous flush contained 5 mg/L nimodipine as a hospital standard. Overall, there was a need for additional

**Table 1.** Summary of n = 12 patients treated with stent retriever angioplasty after SAH: mRS = modified Rankin Scale, MCA = middle cerebral artery, ICA = internal carotid artery, PCOM = posterior communicating, ACOM = anterior communicating, BA = basilar artery, AVF = arteriovenous fistula.

Case	Age (y)	Sex	Bleeding source	Modified		Therapy	Symptomatic Vasospasms	New Infarctions		mRS		FU days after SAH
				Hunt&Hess Grade	Fisher Grade			post-procedure	mRS pre-procedure	discharge	mRS FU	
1	45	f	MCA	3	4	Clipping	Y	n	5	3	0	188
2	55	m	non-aneurysmal	1	2	-	Y	n	4	1	0	163
3	49	f	iatrogenic	-	4	-	Y	y	5	3	-	-
4	78	m	non-aneurysmal	3	4	-	NA	n	5	6	-	-
5	33	f	PCOM	4	4	Coiling	NA	n	5	4	1	77
6	45	f	PCOM	1	2	Coiling	NA	n	5	4	0	226
7	66	f	ICA	4	4	Coiling	NA	n	5	4	4	97
8	32	f	MCA	3	3	Clipping	NA	n	5	5	4	158
9	53	f	AVF	-	-	Embolization with Onyx	Y	n	5	5	-	-
10	57	m	ACOM	2	2	Coiling	N	n	5	4	0	160
11	47	m	MCA	1	4	Clipping	NA	n	5	1	-	-
12	54	m	BA	2	4	Coiling + Stent	NA	n	5	4	-	-

treatment with mechanical balloon-PTA in the same session in 5/21 segments (41.7%).

The effect of stent retriever angioplasty was significantly associated with the vessel-segment: In distal segments a significantly higher restoration of vessel-diameter was achieved compared to more proximal segments (56.6% vs. 26.7%,  $p < 0.05$ ). Furthermore, the size of the stent-retriever had a non-significant influence on restoration of vessel-lumen with reduction of stenosis of 43.6% with 3 mm-retrievers versus 25.8% in 4 mm-retrievers ( $p = 0.059$ ). However, there was no difference in choice of the stent-retriever type used. The adjustable devices did not show a difference in efficacy compared to non-adjustable devices. The results are summarized in Figure 3.

In 2/21 segments (9.52%) a repeated treatment was necessary and performed with a stent retriever angioplasty in a different session. In 5/21 segments (23.8%) local nimodipine was administered via the distal access catheter up to 5 mg (diluted in 50 ml NaCl) over 30 min per treated side in a subsequent session due to recurrent peripheral spasms not affecting the primarily treated segments. In one patient two further balloon-PTAs of the same segments were performed due to recurrent severe vasospasms.

### Complications

Procedure-related complications as dissection, rupture or thromboembolic events did not occur. New infarctions post-procedure were observed in only one patient with anterior cerebral artery rupture during balloon-PTA and following coil-embolization of the affected vessel. Stent retriever angioplasty was conducted contralateral afterwards in this patient (segment 3).

### Clinical outcome

In one patient an immediate improvement of clinical status could be observed post-procedure. Most patients remained intubated after treatment. At discharge, a median mRS of 4 (range 1–6) was observed. One patient died during the hospital stay.

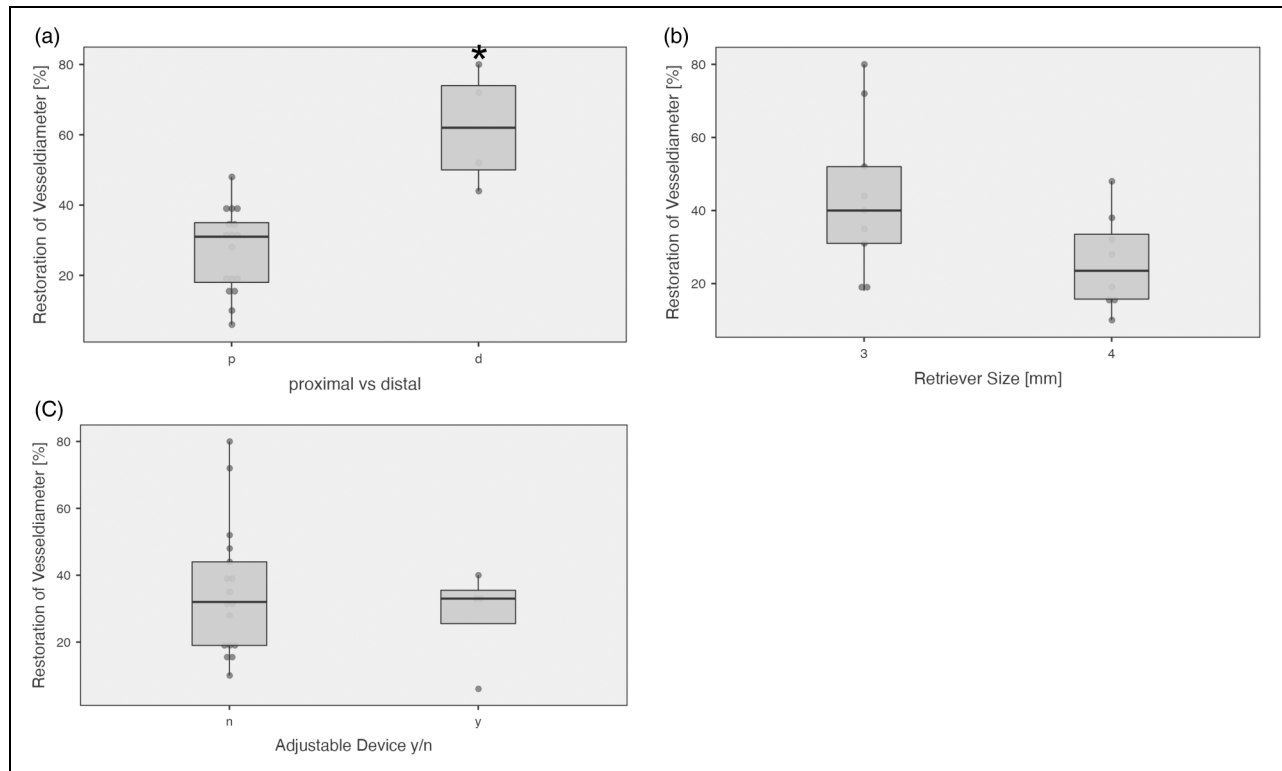
Follow-up data are available in 7 of 12 patients with a median FU-interval of 160 days (range 77–226) after initial SAH with 5 of them (71.4%) showing favorable outcome with mRS 0–1. 4 of 12 patients were lost to follow-up.

### Discussion

Treatment of cerebral vasospasm poses a major challenge in the management of patients with subarachnoid hemorrhage and DAI remain the main cause of worse clinical outcome in many SAH-patients.<sup>1</sup> In addition to medical treatment, interventional catheter-based therapy using local intra-arterial nimodipine administration and/or balloon-PTA plays a key role in the therapy of this disease.<sup>11,12</sup> A recent study shows the feasibility and safety of treating vasospasm with stent-retrievers in a small collective.<sup>13</sup>

**Table 2.** Summary of angioplasty treatment: n = 21 segments in n = 12 patients. M = middle cerebral artery, A = anterior cerebral artery, BA = basilar artery; effect: + = persisting stenosis of  $\leq 30\%$ , -/ + = of 31–50%, - = > 50%; nimodipine: b = before, d = during, a = after stent retriever angioplasty; additional balloon-PTA: p = proximal segment, s = same segment; \* additional IA nimodipine administration on the next day due to peripheral spasms; # additional balloon-PTA of same M1-segment 2 and 5 days later.

segment nr.	patient nr.	Side	segment	day after SAH	retriever-type		stenosis		restoration of vessel diameter (%)		effect	Nimo IA	Additional balloon-PTA	retreatment
					type	size (mm)	pre (%)	post (%)	pre (%)	post (%)				
1	1	R	M2	9	pRESET 3mm	3	80	0	80	80	+	a	p	n
2	1	-	BA	9	pRESET 3mm	3	72	41	31	31	-/+	b	n	n
3	2	I	A1/2	7	Trevo 4mm	4	38	0	38	38	+	n	n	n
4	2	I	M1/2	7	Trevo 4mm	4	61	29	32	32	+	n	n	y
5	2	I	M1/2	8	Trevo 3mm	3	67	50	18	18	-/+	n	n	n
6	3	r	A2/3	8	Trevo 3mm	3	84	12	72	72	+	n	n	n
7	4	r	M1	9	Trevo 4mm	4	61	45	16	16	-/+	b	n	n
8	5	r	M1	4	Trevo 4mm	4	40	12	28	28	+	a	p	n
9	6	r	M1/2	12	Trevo 4mm	4	78	30	48	48	+	n	n	y
10	6	r	M1/2	13	Trevo 4mm	4	65	55	10	10	-	b	n	y#
11	7	r	M1	7	Trevo 3mm	3	65	45	20	20	-/+	b	n	n
12	7	r	A2/3	9	Trevo 3mm	3	53	18	35	35	+	a	n	n
13	7	r	M2	9	Trevo 3mm	3	83	39	44	44	-/+	b	n	n
14	8	r	C7/M1	10	Trevo 4mm	4	65	51	15	15	-	d	n	n
15	8	r	A1/2	10	Trevo 4mm	4	54	35	19	19	-/+	b	n	n
16	9	r	A2/3	10	Trevo 3mm	3	71	19	52	52	+	a	n	y*
17	9	I	A1/2	10	Trevo 3mm	3	72	32	40	40	-/+	a	s	y*
18	10	r	M1	6	Comaneci petit	var	67	35	32	32	-/+	a	n	y*
19	10	I	M1	6	Comaneci petit	var	50	10	40	40	+	a	n	y*
20	11	r	M1	7	Tiger 21	var	62	28	34	34	+	a	n	n
21	12	I	M1	13	Comaneci	var	61	40	21	21	-/+	a	sp	y*



**Figure 1.** (segment 16) A: Severe vasospasms in the ACA (arrows) with significantly delayed perfusion; B: Deployed retriever-stent (Trevor 3 mm; white arrows) from ACOM (A1) to proximal pericallosal artery (A3); C: Successful restoration of vessel lumen and flow.

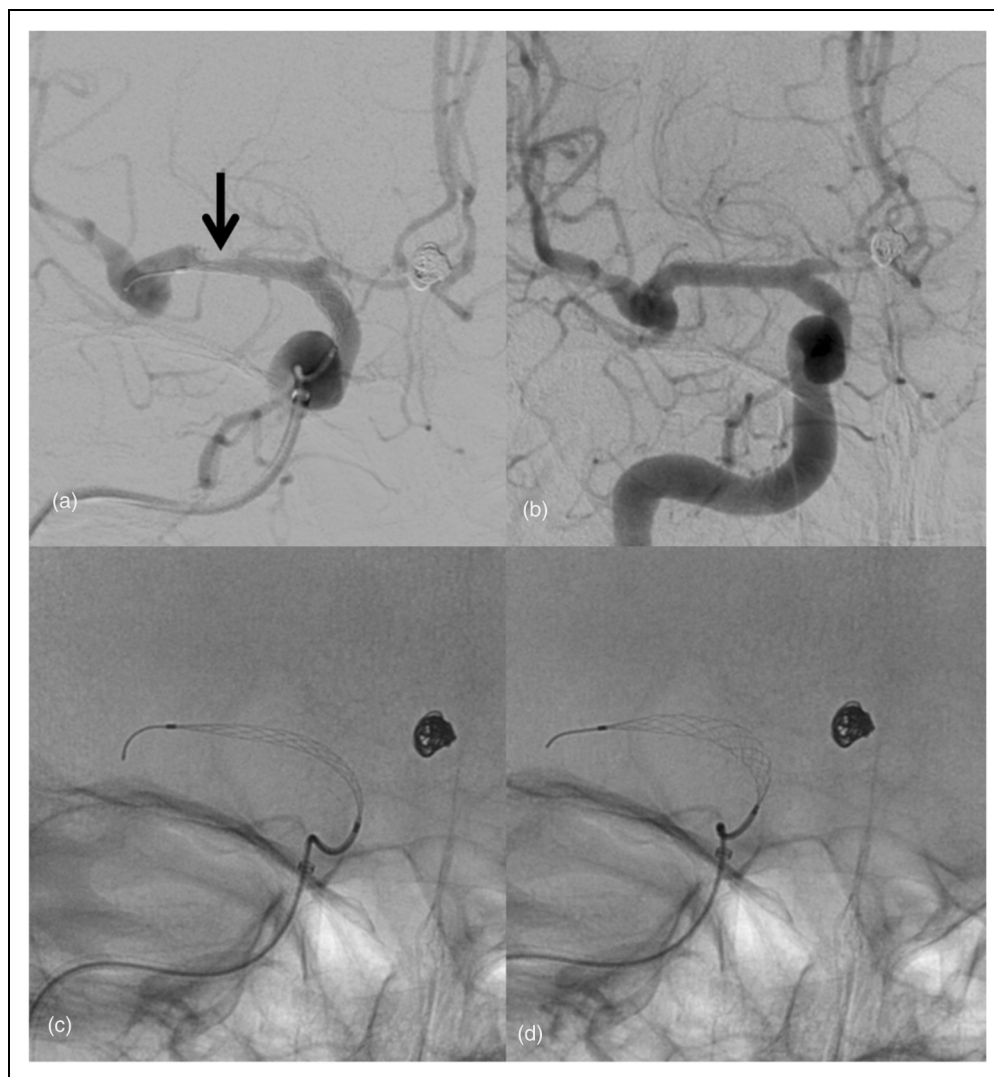
Our results show that interventional spasmolysis with stent-retrievers could be performed without complications in 12 patients with overall 21 vessel-segments. However, in most patients additional intra-arterial nimodipine administration was necessary to achieve sufficient spasmolysis. Local nimodipine administration alone has the advantage of a reduced risk of vascular injury as no mechanical force is applied; however, its efficacy is limited especially in more proximal and severe spasms. Furthermore, the duration of the spasmolytic effect is often limited, which leads to the need for follow-up interventions.<sup>5</sup> Permanent intra-arterial administration of nimodipine can be considered in cases with refractory vasospasm but carries a considerable risk of thromboembolic events.<sup>14</sup>

In our series local nimodipine was administered before, during or after stent retriever angioplasty, depending on the presence of additional peripheral manifestation of the vasospasms in small vessels. However, we did not investigate the effect of the timing of the intra-arterial administration of nimodipine on the efficacy of stent retriever angioplasty. It may, however, be conceivable that prior administration of a spasmolytic agent can improve the efficacy of stent retriever angioplasty, as the retrospective case series of Kwon et al. showed.<sup>10</sup> In summary, administration of nimodipine during and after the retriever maneuver seems promising, as suggested by Bhogal and colleagues.<sup>8</sup> However, our results suggest, that the combination of local nimodipine and stent retriever angioplasty can offer an effective and safe treatment option regardless of the timing of

administration, because small and medium caliber vessels are treated simultaneously.

Balloon-PTA as a first choice has some notable disadvantages as the risk of vessel rupture increases with more peripheral procedures beyond first-order branches whereas stent-retrievers apply a controlled radial force and can safely be applied also in second- and third-order branches with lumen diameters of only 1.5 mm. Furthermore, during PTA the treated vascular segment remains occluded, which can lead to an exacerbation of ischemia in an already compromised circulation due to vasospasms,<sup>15</sup> while stent-retrievers on the other hand promptly facilitate reperfusion.

As there are many different types of retrievers available on the market, a heterogeneous array of stent-retrievers was employed in this study. When deciding upon the choice of stent-retriever model, various aspects must be considered. The radial force of the retriever depends on size and design. Our results demonstrate a non-significant advantage of 3 mm devices compared to 4 mm devices in terms of vessel diameter restoration. However, in our study 4 mm retrievers were only used in more proximal segments and might therefore have shown a minor efficacy. Interestingly, the properties of different devices have been comprehensively described by Machi et al. in their in-vitro study, showing the Trevor 4 mm to exhibit the highest radial force density. The radial force also depends significantly on the caliber, which makes the future investigation of adjustable devices interesting.<sup>16</sup> Moreover, the Trevor XP and the Comaneci have the advantage of a good visibility, facilitating direct visual



**Figure 2.** (segment 18) A: “Deflated” Comaneci petit in severe vasospasm in the right M1-segment (arrow) with significantly delayed perfusion; B: Successful restoration of vessel lumen and flow after “inflation” of the Comaneci petit; C and D: “Deflated” and “inflated” Comaneci petit.

assessment of the spasmolytic effect. However, the inferior radial force of stent-retrievers might be detrimental in more proximal vessel segments compared to the balloon. Here, the use of larger-sized retrievers may be beneficial, but less advantageous in peripheral segments, as stent-retrievers have a lower radial force in a vessel diameter significantly less than the nominal diameter of the stent.<sup>16</sup>

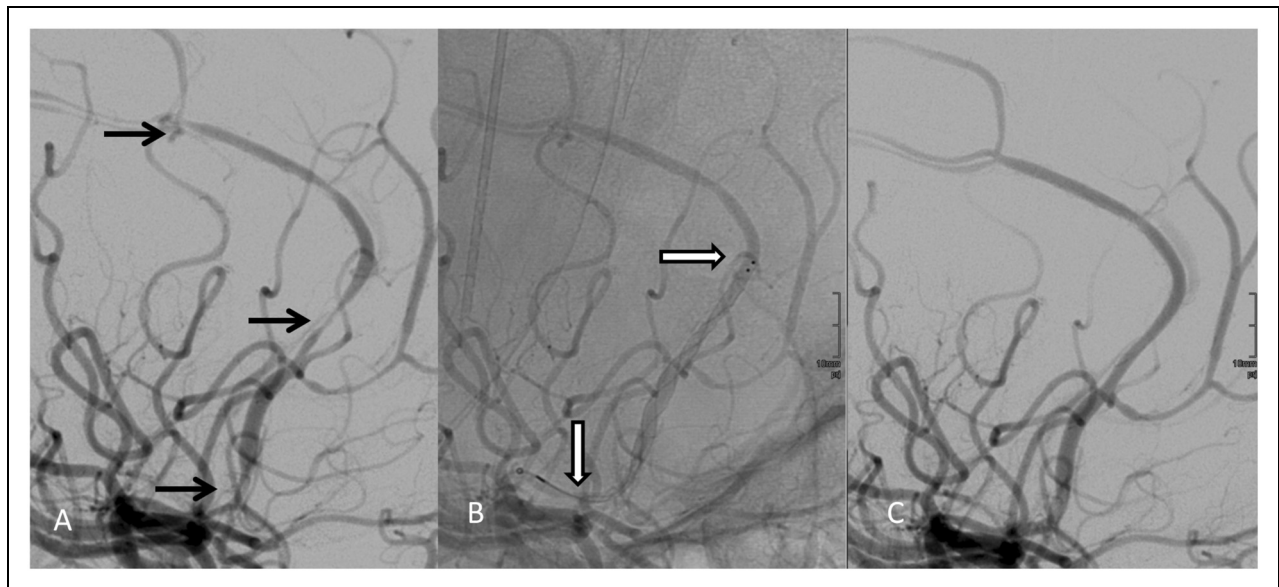
The Comaneci as well as the Tigertriever have the advantage of an adjustable radial force and good visual control due to their radiopacity. This allows for a flexible adjustment in vessel segments of different order and size. In our study, we report for the first time that a good spasmolytic effect without the additional use of balloon-PTA can be achieved with the Comaneci petit and Tigertriever, although these devices were not yet used in distal vessel segment in our study. Regarding manually adjustable devices, only one case showing the feasibility of the Comaneci 17 device has been published so far.<sup>17</sup>

Deployment time might have an influence on the efficacy and duration of the spasmolytic effect and should

be investigated in future studies. However, by maintaining blood flow during angioplasty, there is little argument against a more prolonged deployment time of the retriever as nimodipine can be administered during deployment as described above.<sup>8</sup>

As our data show, especially with pronounced spasms in the larger, proximal vessels such as the distal ICA, a stronger radial force is necessary, which cannot be achieved with the currently available retrievers. The combination of both methods - balloon-PTA for proximal and stent-retriever-dilatation for more distal vessel segments - offers the interventionalist more options in the quest for satisfactory results. For the future we see substantial potential to develop new devices based on stent-retriever technology for this particular pathology.

Our study has limitations due to its observational, retrospective, single-center design. The small sample size precludes sufficient statistical results and therefore can only demonstrate the technical proof of a new interventional concept. Furthermore, we have not yet standardized the procedure in terms of indication for use of stent-retrievers,



**Figure 3.** Restoration of vessel diameter (%): difference of most severe stenosis pre and post spasmolysis with stent-retriever depending on (A) distal and proximal vessel segments, (B) size of stent-retriever and (C) adjustable devices compared to non-adjustable devices. Data are expressed as boxplot with mean  $\pm$  SD, \* =  $p < 0.05$  (Mann-Whitney test).

choice of the stent-retriever model and combination with other interventional treatments such as local nimodipine and/or balloon-PTA. Nevertheless, we have been able to demonstrate that stent-retrievers can be used safely in patients with vasospasms, and they extend the endovascular portfolio for neurointerventionalists in the treatment of SAH-induced vasospasms. Additionally, the occurrence of new infarctions in only one case and a favorable outcome in most patients at FU are encouraging. However, the investigation of interventional vasospasm treatment remains complicated, as there is no standardization of definitions and thresholds for cerebral vasospasms so far with very heterogeneous data in the literature.<sup>18</sup>

## Conclusion

Vasospasms contribute considerably to a high morbidity and mortality after subarachnoid hemorrhage. Effective spasmolytic therapy still poses a great challenge to interventionalists. Conservative therapy, the local administration of vasodilators and angioplasty using balloon-PTA are the current therapeutic options. Stent-retrievers may be an effective and safe alternative or adjunct in cerebral vasospasm therapy, especially in smaller second- or third-order branches. They could provide greater efficacy and longer duration in comparison to the local administration of nimodipine, while mitigating the disadvantages of balloon-PTA, particularly the risk of rupture.

## Ethical approval statement

All procedures performed in studies involving human participants were in accordance with the ethical standards of the institutional and/or national research committee and with the 1964 Helsinki declaration and its later amendments or comparable ethical standards. For this type of study formal consent is not required.

## Declaration of conflicting interests


The author(s) declared the following potential conflicts of interest with respect to the research, authorship, and/or publication of this article: Johannes Hensler: Personal fees from consultant activity for Balt outside the submitted work Fritz Wodarg: Personal fees from consultant activity for Microvention, personal fees from consultant activity for Acandis, personal fees from consultant activity for Balt, personal fees from consultant activity for Cerenovus outside the submitted work. Jawid Madjidyar: none. Sönke Peters: none. Gesa Cohrs: none. Olav Jansen: Personal fees from consultant activity for STRYKER, personal fees from consultant activity for Medtronic, personal fees from consultant activity for Covidien, outside the submitted work. Naomi Larsen: Personal fees from consultant activity for Balt outside the submitted work

## Funding

The author(s) received no financial support for the research, authorship, and/or publication of this article.

## ORCID iDs

J Hensler  <https://orcid.org/0000-0002-6594-5334>

F Wodarg  <https://orcid.org/0000-0003-1413-2699>

## References

1. Harrod CG, Bendok BR and Batjer HH. Prediction of cerebral vasospasm in patients presenting with aneurysmal subarachnoid hemorrhage: a review. *Neurosurgery* 2005; 56: 633–654. discussion 633–654.
2. Munakata A, Ohkuma H, Nakano T, et al. Effect of a free radical scavenger, edaravone, in the treatment of patients with aneurysmal subarachnoid hemorrhage. *Neurosurgery* 2009; 64: 423–428. discussion 428–429. DOI: 10.1227/01.NEU.0000338067.83059.EB.
3. Dankbaar JW, de Rooij NK, Velthuis BK, et al. Diagnosing delayed cerebral ischemia with different CT modalities in patients with subarachnoid hemorrhage with clinical deterioration. *Stroke* 2009; 40: 3493–3498.

4. Jabbarli R, Pierscianek D, Rolz R, et al. Endovascular treatment of cerebral vasospasm after subarachnoid hemorrhage: more is more. *Neurology* 2019; 93: e458–e466. 2019/07/07. DOI: 10.1212/WNL.0000000000007862.
5. Connolly ES Jr., Rabinstein AA, Carhuapoma JR, et al. Guidelines for the management of aneurysmal subarachnoid hemorrhage: a guideline for healthcare professionals from the American heart association/American stroke association. *Stroke* 2012; 43: 1711–1737.
6. Khatri R, Memon MZ, Zacharatos H, et al. Impact of percutaneous transluminal angioplasty for treatment of cerebral vasospasm on subarachnoid hemorrhage patient outcomes. *Neurocrit Care* 2011; 15: 28–33.
7. Hollingworth M, Chen PR, Goddard AJ, et al. Results of an international survey on the investigation and endovascular management of cerebral vasospasm and delayed cerebral ischemia. *World Neurosurg* 2015; 83: 1120–1126. e1121. 2015/02/15. DOI: 10.1016/j.wneu.2015.01.036.
8. Bhogal P, Loh Y, Brouwer P, et al. Treatment of cerebral vasospasm with self-expandable retrievable stents: proof of concept. *J Neurointerv Surg* 2017; 9: 52–59.
9. Bhogal P, Paraskevopoulos D and Makalanda HL. The use of a stent-retriever to cause mechanical dilatation of a vasospasm secondary to iatrogenic subarachnoid haemorrhage. *Interv Neuroradiol* 2017; 23: 330–335.
10. Kwon HJ, Lim JW, Koh HS, et al. Stent-Retriever angioplasty for recurrent post-subarachnoid hemorrhagic vasospasm - A single center experience with long-term follow-up. *Clin Neuroradiol* 2018. DOI: 10.1007/s00062-018-0711-3. 2018/08/08.
11. Zubkov YN, Nikiforov BM and Shustin VA. Balloon catheter technique for dilatation of constricted cerebral arteries after aneurysmal SAH. *Acta Neurochir (Wien)* 1984; 70: 65–79.
12. Mortimer AM, Steinfort B, Faulder K, et al. The detrimental clinical impact of severe angiographic vasospasm may be diminished by maximal medical therapy and intensive endovascular treatment. *J Neurointerv Surg* 2015; 7: 881–887.
13. Su YS, Ali MS, Pukenas BA, et al. Novel treatment of cerebral vasospasm using solitaire stent retriever-assisted angioplasty: case series. *World Neurosurg* 2020; 135: e657–e663. 2019/12/28. DOI: 10.1016/j.wneu.2019.12.097.
14. von der Brelie C, Doukas A, Stopfer A, et al. Clinical course and monitoring parameters after continuous interventional intra-arterial treatment in patients with refractory cerebral vasospasm. *World Neurosurg* 2017; 100: 504–513.
15. Adami D, Berkefeld J, Platz J, et al. Complication rate of intraarterial treatment of severe cerebral vasospasm after subarachnoid hemorrhage with nimodipine and percutaneous transluminal balloon angioplasty: worth the risk? *J Neuroradiol* 2019; 46: 15–24. 2018/05/08. DOI: 10.1016/j.neurad.2018.04.001.
16. Machi P, Jourdan F, Ambard D, et al. Experimental evaluation of stent retrievers' mechanical properties and effectiveness. *J Neurointerv Surg* 2017; 9: 257–263.
17. Badger CA, Jankowitz BT and Shaikh HA. Treatment of cerebral vasospasm secondary to subarachnoid hemorrhage utilizing the Comaneci device. *Interv Neuroradiol* 2020; 26: 582–585. 2020/07/30. DOI: 10.1177/1591019920945554.
18. Darsaut TE, Derksen C, Farzin B, et al. Reliability of the diagnosis of cerebral vasospasm using catheter cerebral angiography: a systematic review and inter- and intraobserver study. *AJNR American journal of neuroradiology* 2021. DOI: 10.3174/ajnr.A7021. 2021/01/30.



Copyright of Interventional Neuroradiology is the property of Sage Publications, Ltd. and its content may not be copied or emailed to multiple sites or posted to a listserv without the copyright holder's express written permission. However, users may print, download, or email articles for individual use.